

Trauma and reconstruction

## Urinary tract foreign body: A case of panurethral and intravesical spray foam insulation

Rosa Park<sup>a</sup>, Susan M. MacDonald<sup>b,\*</sup><sup>a</sup> Division of Urology, Northport VA Medical Center, Northport, NY, USA<sup>b</sup> Division of Urology, Penn State Health Milton S. Hershey Medical Center, 500 University Drive, P.O. Box 850, Hershey, PA, USA

## ARTICLE INFO

## Keywords:

Urethra  
Foreign body  
Urethral stricture  
Polyembolokoilamania  
Urethrotomy

## ABSTRACT

Foreign bodies are inserted into the genitourinary tract for various reasons, and may present a challenge to remove. We report a case of foam insulation injected into the urethra almost entirely occluding the urethra and filling the bladder. Ultimately both a cystostomy and perineal urethrotomy were required for removal.

## Introduction

Multiple cases of foreign objects inserted into the urethra have been described. Nonetheless, it is a relatively rare occurrence.<sup>1–3</sup> These foreign objects are typically inserted due to psychiatric illness, intoxication, or autoeroticism.<sup>2</sup> Polyembolokoilamania is the insertion of foreign objects into body orifices for sexual gratification.<sup>4</sup> Removal of the foreign object may present a challenge depending on the size, shape and location. These objects can cause pain, hematuria, and trauma to the urethra ultimately leading to urethral stricture disease. We present the case of a male patient who inserted a long straw into his urethra for sexual gratification and inadvertently injected spray foam insulation into the full length of his urethra filling his bladder.

## Case report

A 45-year-old male patient presented to the emergency department with hematuria and difficulty with urination. He had been inserting various objects into his urethra as an aid for erectile dysfunction. His partner had inserted a straw attached to a can of weatherproofing spray foam into his urethra three weeks prior and inadvertently pressed the button deploying the foam. Since then, he had progressively worsening difficulty with urination, dysuria, and gross hematuria with urinary retention. Computed tomography (CT) of the abdomen and pelvis showed radiolucent foreign material in the nondependent bladder measuring 10.7 × 4.3 × 6 cm. There was additional radiolucent foreign

material noted in the penis measuring up to 16mm in width (Fig. 1).

After obtaining informed consent, the patient was taken to the operating room for removal of the foreign body. He underwent open cystostomy with removal of foreign body, cystourethroscopy, urethral dilation, perineal urethrotomy and closure of perineal urethrotomy. The spray foam was removed from the bladder and prostatic urethra first through a cystostomy. An attempt was made to remove the spray foam in the urethra endoscopically in an antegrade fashion from the cystostomy using a basket, however the patient had urethral stricture disease and the narrow portions of his urethra anchored the spray foam in place. Ultimately a perineal urethrostomy was required to remove the remaining fragments (Fig. 2). Intraoperative findings showed multiple anterior urethral strictures, however, an approximately 10 French midshaft urethral stricture limited the passage of the cystoscope. A 20-french suprapubic tube, 14-french urethral catheter, and pelvic drain were ultimately placed. The postoperative course was unremarkable with a retrograde urethrogram at three weeks showing no contrast extravasation from the urethra. The drain and urethral catheter were removed and the patient has been managed subsequently with a suprapubic tube in anticipation of a urethral repair.

## Discussion

Various objects inserted into the urethra have been reported. These can vary from common household items such as straws, cotton tipped swabs, or batteries to more industrial items such as nails and cable

\* Corresponding author. Division of Urology, Penn State Health Milton S. Hershey Medical Center, 500 University Drive, P.O. Box 850, Hershey, PA, 17033-0850, USA.

E-mail address: [smacdonald@pennstatehealth.psu.edu](mailto:smacdonald@pennstatehealth.psu.edu) (S.M. MacDonald).

<https://doi.org/10.1016/j.eucr.2020.101363>

Received 25 June 2020; Received in revised form 22 July 2020; Accepted 26 July 2020

Available online 29 July 2020

2214-4420/© 2020 The Authors.

Published by Elsevier Inc.

This is an open access article under the CC BY-NC-ND license

(<http://creativecommons.org/licenses/by-nc-nd/4.0/>).

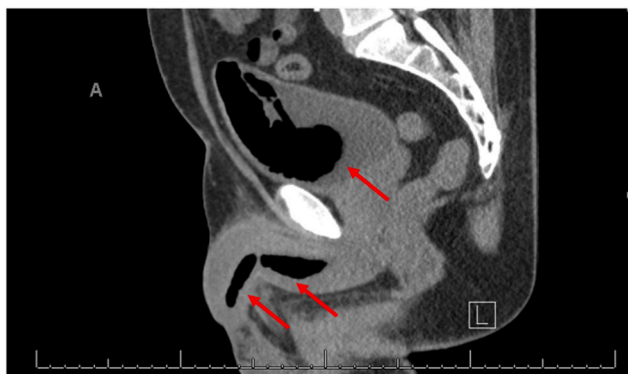


Fig. 1. CT Scan: Arrows point to spray foam within the urinary tract.

wires.<sup>1-3,5</sup> These objects can then migrate proximally becoming irretrievable without medical intervention. Patients with urethral foreign bodies typically present with dysuria, hematuria, urethral discharge, and obstructive voiding symptoms. Patients with intravesical foreign bodies may present with acute cystitis reporting symptoms of urinary frequency, painful voiding and hematuria. Occasionally patients are asymptomatic.

Reasons for insertion of a foreign body into the genitourinary tract include mental illness, borderline personality disorder, sexual gratification, or temporary release from imprisonment to seek medical attention.<sup>2</sup> Unfortunately, many patients are repeated offenders and thus psychiatric evaluation to prevent recurrent injury should be considered. Our patient achieved a stable relationship partner, but has been homeless and thus sporadically followed up with suprapubic tube changes. He

has not been referred to psychiatry as he has not had any repeat episodes since his operation, but would be referred prior to consideration of reconstruction when he achieves a stable living environment. Additionally, due to embarrassment, patients may delay seeking treatment. Patients require careful examination and sometimes diagnostic imaging. Plain films may help identify the object but CT images may be required for radiolucent objects.

Palmer's group at Cook County Hospital developed an algorithm for foreign body removal after a retrospective review of 35 episodes of urethral foreign bodies.<sup>3</sup> Palmer et al. suggest that small (<1cm), palpable, mobile objects in the distal urethra could potentially be "milked" and manually extracted if not readily able to be urinated out. More proximal location, larger, or immobile objects will likely require imaging and likely operative intervention. A detailed description of the item or visualization on imaging will help in determining size, shape, consistency of the material to plan an ideal method for retrieval.<sup>5</sup> Objects in the urethra can be removed endoscopically, however, impacted objects may require open urethrotomy. Foreign bodies with a significant intravesical component will require open cystotomy. In the case of our patient, he had a large intravesical component that was attached to the intraprostatic portion; an open cystotomy was required. His pre-existing urethral stricture disease made removal of the hardened foam using endoscopic graspers through the urethra impossible. The normal caliber segments created a wide foam cast that would not pass through the narrowed stricture segments. Thus, attempts to remove the urethral portion of the foam in an antegrade fashion from the cystotomy were not successful.

We recommend treating these patients with antibiotics. Complications following removal include urinary tract infection, sepsis, urethral false passage, laceration and new onset or worsened urethral stricture

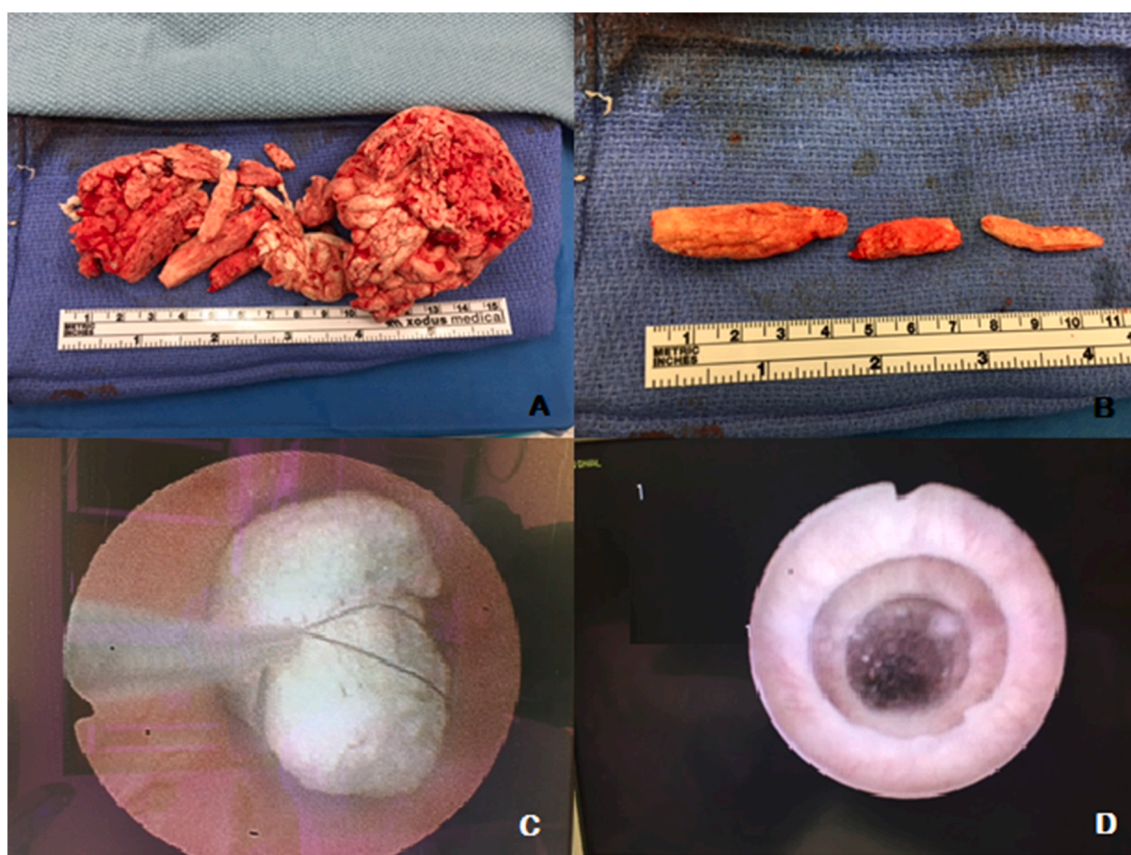


Fig. 2. A. Total amount of spray foam insulation retrieved from the urinary tract. B. The spray foam insulation retrieved from the urethra. C. Attempted endoscopic remove of urethral spray foam in an antegrade fashion from the cystotomy. D. Urethra demonstrating multiple rings of long standing stricture disease making endoscopic removal impossible.

disease. Surveillance of these patients for complications or stricture disease is warranted.

## References

1. Rahman NU, Elliott SP, McAninch JW. Self-inflicted male urethral foreign body insertion: endoscopic management and complications. *BJU Int.* 2004;94(7): 1051–1053.
2. van Ophoven A, deKernion JB. Clinical management of foreign bodies of the genitourinary tract. *J Urol.* 2000;164(2):274–287.
3. Palmer CJ, Houlihan M, Psutka SP, Ellis KA, Vidal P, Hollowell CM. Urethral foreign bodies: clinical presentation and management. *Urology.* 2016;97:257–260.
4. Chan G, Mamut A, Tatzel S, Welk B. An unusual case of polyembolokoilamania: urethral avulsion from foreign object use during sexual gratification. *Can Urol Assoc J.* 2016;10(5-6):E181–E183.
5. Young MJ, Noblet T, Symons SJ. Surgical technique for the delayed removal of superglue from the male urethra. *Cent European J Urol.* 2016;69(3):290–292.